

Carcinoma of the breast

Aetiological factors

- 1) Biographical factors: it is common in western world & less in the developing countries. It is rare in Japan.
- 2) Age, CA breast is extremely rare below 20 yrs.
The incidence increase with age & at age of 90 yrs., more than 20% affected.
- 3) Gender. In male the incidence is only < 0.5%.
- 4) Genetic. It is more common in females with positive family history for breast CA than in the general population.

Breast CA due to specific mutation account for 5% of cause. Presence of mutation in BRCA & BRCA2 increases the risk for CA breast by $\cong 60\%$.

The presence of breast CA in the mother or sister increases the risk by 2.3 times while the presence of the disease in both the mother & sister increase the risk by 14 times.

- 5) Diet. It plays a role as it is more common in western world. Obesity & high intake of saturated fat are associated with increased risk.

In obese, there is increase conversion of oestrogen into oestradiol in the body fat.

- 6) Endocrine factors

CA breast is common in nulliparous women, females with early menarche & late menopause.

The following in protective against breast CA.

- 1) *Having the first child at an early age.*
- 2) *Breast feeding*
- 3) *Late menarche & early menopause.*

- 7) The role of oral contraceptive pills (exogenous estrogen) & hormone replacement therapy in the development of CA breast is more controversial.

- 8) Pre cancerous lesions include

- a) Moderate or florid epithelial hyperplasia & duct papilloma increase the risk by 1-5-2 times.
- b) A typical epithelial hyperplasia increases the risk by 2-5 times.
- c) Lobular or ductal carcinoma in situ increases the risk by 5-10 times.
- d) Previous affection with breast CA.

Patient with breast CA in one side, have an increased risk to develop cancer in the other breast.

Pathology

Breast cancer may arise from the epithelium of the duct system anywhere from the nipple end of major lactiferous ducts to the terminal duct unit which is in the breast lobule. It may be entirely in situ or may be invasive cancer. The degree of differentiation of the tumour is usually described by three grades — well differentiated, moderately or poorly differentiated. **Ductal carcinoma** is the most common variant, but **lobular carcinoma** occurs in up to 10 per cent of cases. Rarer histo-logical variants, usually carrying a better prognosis, include **colloid carcinoma** whose cells produce abundant mucin, **medullary carcinoma** with solid sheets of large cells often associated with a marked

lymphocytic reaction and **tubular carcinoma**. Invasive lobular carcinoma is commonly multi-focal and/or bilateral.

Inflammatory carcinoma is a fortunately rare, highly aggressive cancer which presents as a painful, swollen breast, which is warm with cutaneous oedema. This is due to blockage of the subdermal lymphatics with carcinoma cells. Inflammatory cancer usually involves at least one-third of the breast and may mimic a breast abscess. A biopsy will confirm the diagnosis and show undifferentiated carcinoma cells.

In situ carcinoma is preinvasive cancer which has not breached the epithelial basement membrane. This was previously a rare, usually asymptomatic finding in breast biopsy specimens but is becoming increasingly common owing to the advent of mammographic screening — it accounts for 20 per cent of cancers detected by screening. In situ carcinoma may be ductal (**DCIS**) or lobular (**LCIS**), the latter often multifocal and bilateral. Both are markers for the later development of invasive cancer which will go on to develop in at least 20 per cent of cases.

Paget's disease of the nipple

Paget's disease of the nipple is a superficial manifestation of an underlying breast carcinoma. It presents as an eczema-like condition of the nipple and areola which persists in spite of local treatment. The nipple is eroded slowly and eventually disappears. If left, the underlying carcinoma will sooner or later become clinically evident. Thus nipple eczema should be biopsied if there is any doubt about its cause.

After the paget's disease of the nipple has been confirmed with punch biopsy of the nipple areola complex, the traditional surgical treatment is mastectomy with or without axillary dissection.

Spread of mammary carcinoma

1. Local spread.

The tumour increases in size and invades other portions of the breast. It tends to involve the skin and to penetrate the pectoral muscles, and even the chest wall.

2. Lymphatic metastasis

Occurs primarily to the axillary lymph nodes and to the internal mammary chain of lymph nodes. In advanced disease there may be involvement of supraclavicular nodes and of any contralateral lymph nodes.

3. Spread by the bloodstream.

It is by this route that skeletal metastases occur (in order of frequency) in the lumbar vertebrae, femur, thoracic vertebrae, rib and skull; they are generally osteolytic. Metastases may also occur in the liver, lung and brain, and occasionally the adrenal glands and ovaries.

Clinical presentation

While any portion of the breast, including the axillary tail, may be involved, breast cancer commences most frequently in the upper, outer quadrant. Most breast cancers will present as a *hard lump*, which may be associated with *indrawing of the nipple*. As the disease advances locally there may be skin involvement with *peau d'orange* or *frank ulceration and fixation to the chest*

wall. This is described as *cancer-en-cuirasse*. About 5 per cent of breast cancers will present with either *locally advanced disease or symptoms of metastatic disease*.

Staging evaluation

The full extent of the disease can be ascertained. In patient with *cancer-en-cuirasse* this will include a careful clinical examination, chest X-ray, serum alkaline phosphatase and gamma glutamine transaminase (GGT), with liver ultrasound if these are abnormal, and an isotope bone scan. This is important for both prognosis and treatment — a patient with widespread visceral metastases may obtain an increased length and quality of survival from systemic hormone or chemotherapy, but she is not likely to benefit from surgery as she will die from her metastases before local disease becomes a problem.

In contrast, patients with relatively *small* (less than 5 cm in diameter) tumours confined to the breast and ipsilateral lymph nodes rarely need staging beyond a good clinical examination as the pick-up rate for distant metastases is so low.

Phenomena resulting from lymphatic obstruction in advanced breast cancer

- ✚ ***Peau d'orange*** is due to cutaneous lymphatic oedema. Where the infiltrated skin is tethered by the sweat ducts it cannot swell, leading to an appearance like orange skin.
- ✚ ***Late oedema of the arm*** is a troublesome complication of breast cancer treatment fortunately seen less often now that *radical axillary dissection* and *radiotherapy* are rarely combined. It does however occasionally still occur after either modality of treatment alone and appears anytime from months to years after treatment. There is usually no precipitating cause but *recurrent tumour* should be excluded as neoplastic infiltration of the axilla can cause arm swelling due to *both lymphatic and venous blockage*.

Treatment

An oedematous limb is susceptible to bacterial infections following quite minor trauma, and these require vigorous antibiotic treatment. Treatment of late oedema is difficult but limb elevation, elastic arm stockings and pneumatic compression devices can be useful.

✚ **Cancer-en-cuirasse**

The skin of the chest is infiltrated with carcinoma and has been likened to a coat. It may be associated with a grossly swollen arm. This usually occurs in cases with local recurrence after mastectomy, and occasionally is seen to follow the distribution of irradiation to the chest wall. The condition may respond to palliative systemic treatment but prognosis in terms of survival is poor.

- ✚ **Lymphangiosarcoma** is a rare complication of lymphoedema with an onset many years following the original treatment. It takes the form of multiple subcutaneous nodules in the upper limb. The prognosis is poor but some cases respond to cytotoxic therapy or irradiation.

Staging

There are two traditional systems of classification for breast carcinoma which predominantly rely on clinical staging of the disease. These are the Manchester system and the Inter-national Union Against Cancer TNM (tumour, nodes, metas-tases) staging system.

Prognosis of breast Cancer

The best indicators of prognosis in CA breast are still the

1. Tumour size and 2. Lymph node status.

But some large tumors remain confined to the breast for decades and some small tumours are incurable at the time of diagnosis.

So the prognosis of CA breast, depend not on it's chronologic age but on it's invasive and metastatic potential.

The traditional prognostic & predictive factors for invasive CA breast are classified into those related to the tumour and those related to the host.

❖ Tumour factors that affect the prognosis are:

1. Histological grade of the tumour (nuclear grade).
2. Hormone receptor status.
3. Measures of tumour proliferation e.g S. phase fraction and thymidine labeling index.
4. Growth factor analysis.
5. Oncogen or oncogen product measurements.
6. Nodal status.
7. Tumour size.
8. Lymphatic/ vascular invasion.
9. Extensive intraductal component.

❖ Host factors that affect the prognosis in CA breast:

** Age *menopausal Status * family HX of CA breast * Previous CA breast * presence of immunosuppression * nutritional history of the patient * prior chemo therapy * prior radiotherapy.*

Treatment of cancer of the breast

Treatment will largely depend upon clinical stage of the disease at presentation including not only classical TNM staging but often other tumour characteristics such as tumour grade.

Treatment of early breast Cancer

The aims of treatment are:

1. 'Cure': possible in some patients but recurrence up to 20 years after initial treatment is not uncommon;
2. Control of local disease in the breast and axilla;
3. Conservation of local form and function;
4. Prevention or delay of the occurrence of distant metastases.

Local treatment of early breast cancer

Local control is achieved through surgery and/or radiotherapy.

Surgery

Surgery still has a central role to play in the management of breast cancer

Patey' mastectomy

The breast and associated structures are dissected en bloc and the excised mass is composed of:

- The whole breast;
- A large portion of skin, the centre of which overlies the tumour, but always includes the nipple;
- All of the fat, fascia and lymph nodes of the axilla. The pectoralis minor muscle is either divided or removed to gain access to the upper two-thirds of the axilla. The axillary vein and nerves to serratus anterior and latissimus dorsi should be preserved.

The wound is drained using a wide-bore suction tube.

Early mobilisation of the arm is encouraged and physiotherapy helps normal function to return very quickly

انتبه مهم جدا

Currently, mastectomy with assessment of the axillary lymph nodes and breast conservation (lumpectomy with axillary lymph node dissection through separate incision & radio therapy) are both considered equivalent treatment for stages I & II.

- ❖ Axillary lymphadenopathy or metastatic disease in sentinel axillary lymph nodes necessitates an axillary dissection for lymph nodes.

Contraindications for conservative surgery are:

1. Central disease.
 2. Multifocal.
 3. Recurrent disease.
 4. Larger mass in comparison to the size of the breast
 5. Prior radio therapy to the breast or the chest wall
 6. Involved surgical margins or unknown margin status following re excision.
 7. Scleroderma or other connective tissues disease.
- ❖ **Adjuvant chemotherapy for early invasive breast CA is considered for:**
 1. All node positive CA.
 2. All cancers that are larger than one cm size.
 3. For node negative cancers larger than 0.5cm size when adverse prognostic features is present which include;
 - ❖ Blood or lymphatic vessel invasion.
 - ❖ High nuclear grade.
 - ❖ High histological grade.
 - ❖ HER2/ neu over expression, and;
 - ❖ Negative hormone receptor status.

Tamoxifen therapy is considered for hormone receptor positive women.

HER/2 neu overexpression is determined for all newly diagnosed patients with breast CA and may be used to:

1. Provide prognostic informations in patient with node negative breast CA.
2. Predict the relative efficacy of various chemotherapy regimens.

3. Predict the benefit from herceptin in women with metastatic or recurrent breast CA.

Treatment options in advanced loco-regional breast CA (stage IIIa, IIIb)

- ❖ Those women have advanced loco regional breast CA, but have no clinically detected distant metastasis.
- ❖ In an effort to provide optimal loco regional disease free survival & distant disease- free survival for those women, surgery is integrated with radio therapy & chemo therapy.
- ❖ Stage III patients are divided into those who have operable disease and those who have non operable disease.

Patients with operable stage **IIIa** disease, require modified radical mastectomy followed by adjuvant chemotherapy followed by adjuvant radio therapy.

Patients with non-operable stage **IIIa** and for stage **IIIb**, neoadjuvant chemotherapy is used to decrease the locoregional cancer burden & may permit subsequent surgery to establish locoregional control. In this setting, surgery is followed by adjuvant chemotherapy & adjuvant radio therapy.

Treatment of a female with distant metastasis stage IV breast CA

Treatment for stage **IV** breast is not curative, but may prolong survival.

Hormonal therapy that is associated with minimal toxicity is preferred to cytotoxic chemotherapy.

- ❖ The appropriate candidates for initial hormonal therapy include:
 1. Female with hormone receptor positive CA.
 2. Female with bone or soft tissue metastases only.
 3. Female with limited and asymptomatic visceral metastases.
- ❖ Systemic chemo therapy is indicated for:
 1. Female with hormone receptor negative CA.
 2. Symptomatic visceral metastases.
 3. Hormone refractory metastases.
- ❖ For premenopausal & postmenopausal female with stage 4 disease, an anti estrogen with tamoxifen is the preferred initial treatment.

In women with previous antiestrogen exposure the recommended

second line hormone therapy is as follow:

1. For postmenopausal women give aromatase inhibitor as anastrozole.
2. For premenopausal women give progestins, androgens, high dose estrogen or Oophorectomy (medical, surgical or radio ablative).
 - ❖ Biphosphonate given in addition to women with bone metastases.
- ❖ Radiotherapy for painful bony deposits and internal fixation for pathological fracture.

Notes

Radio therapy is considered (indicated) in the following:

- Extensive local disease with infiltration of the chest wall.
- High grade tumour.
- Large tumour.
- Heavily node positive.
- Extensive lymphovascular invasion.
- Following conservative treatment to reduce the incidence of local recurrence

- Following mastectomy in stage 3 to reduce the incidence of local recurrence

Screening for breast Cancer مهم جدا

It is achieved by exposing the breast to low voltage, high amperage X-ray. The dose is usually 0.1 centigray.

Screening mammography is used to detect unexpected breast CA in asymptomatic women, so it supplement history & clinical examination.

With screening mammography. Two views of the breast are obtained, the craniocaudal view & the mediolateral oblique view. Screening program could detect tumour before they come to the patients notice and this may reduce mortality from breast CA.

Breast screening by mammography over the age of 50 yrs will reduce cause specific mortality by up to 30%.

The national health center launched a program of 3 yearly mammographic screening for females between the ages of 50 & 64 years.

- ❖ Benefits of screening mammography:
 1. Avoid expensive & toxic treatment of advanced CA.
 2. Extra years of productivity.
 3. Reassurance if the screening is negative.
 4. Life years gained because more curable early CA detected.
- ❖ Disadvantages are:
 1. Cost of additional cases treated.
 2. Morbidity of the test.
 3. Over diagnosis e.g. ductal carcinoma insitu.
 4. Anxiety if the screening is positive.
 5. False reassurance for false negative results.
- ❖ Specific mammographic features that suggest a diagnosis of breast CA include:
 1. Solid mass with or with out stellate features.
 2. Asymmetric thickening of the breast tissue.
 3. Clustered micro calcification.
 4. The presence of fine stippled (calcification) calcium in and around suspicion lesion is suggestive of breast CA.

LCIS:

Because LCIS is considered as a marker for increased risk rather than an inevitable precursors of invasive disease, the current treatment of lobular carcinoma insitu is observation with or with out tamoxifen.

LCIS is not invasive disease in the lobules or the terminal ducts. The risk of developing invasive CA which is usually infiltrative ductal carcinoma is 1% per year & it is usually bilateral.

- ❖ The goal of treatment in LCIS is to prevent or detect at an early stage, the invasive CA that subsequently develop in 25-35% of cases.
- ❖ There is no benefit to excise LCIS as the disease diffusely involves both breasts & the risk of invasive CA is equal for both breasts.

The use of tamoxifen as risk reduction strategy should be considered in women with the diagnosis of LCIS.

If *tamoxifen* is contraindicated or if the patient is unable or unwilling to comply with close follow up, *bilateral prophylactic mastectomy* with or with out reconstruction is also an option.

DCIS:

It also called intraductal carcinoma. It carry high risk to develop into invasive CA. It occur in both male & female. Histologically, it is characterized by proliferation of the epithelia that line the minor ducts, causing papillary growth with in the duct Lumina. The growths then will undergo necrosis. Calcium deposits occur in areas of necrosis & are a common mammographic feature.

Treatment of DCIS:

- ❖ If wide spread disease (two or more quadrants) mastectomy is required.
- ❖ If limited disease, lumpectomy & radio therapy is required.
- ❖ If low grade DCIS of the solid cribriform or papillary subtypes which is < 0.5cm in diameter, lumpectomy alone is enough.

Then specimen mammography is performed to ensure that all visible evidence of the disease is excised.

Staining for estrogen and progesterone receptors is now considered routine as their presence will indicate the use of adjuvant hormonal therapy with tamoxifen.

Indeed, adjuvant tamoxifen therapy is considered for all DCIS patients. Patients treated with lumpectomy & radio therapy has the same mortality but higher recurrence rate than if treated by mastectomy.

Management of a case of locoregional recurrence of CA breast للاطلاع

Those are separated into two groups.

- 1) Those having had mastectomy.
 - 2) Those having had lumpectomy.
 - ❖ Women with previous mastectomy, undergo surgical resection of the locoregional recurrence and appropriate reconstruction.
- Chemotherapy and antiestrogen therapy are considered, and adjuvant radiotherapy is given if the chest wall has not previously received radiotherapy.
- ❖ Women with previous breast conservative surgery undergo mastectomy and appropriate reconstruction. Chemotherapy and anti oestrogen therapy are considered.

How you manage breast CA in pregnant female للاطلاع

Specific consideration

The treatment of CA breast in pregnant female is the same for non pregnant female with some exceptions:

1. Radiotherapy should be avoided during pregnancy making mastectomy more frequent option than breast conservative surgery.
2. Chemotherapy should be avoided during the first trimester but safe subsequently.
3. Most tumours are hormone receptor negative and so hormone therapy which is potentially teratogenic is not required.

Becoming pregnant subsequent to the diagnosis of breast CA appear not to alter the likely outcome but if the tumour diagnosed in female, she is advice to

wait 2 years to be pregnant as it is within this time, that recurrence most often occur.

- ❖ The treatment of stage I and II lesions during the first trimester should be with modified radical mastectomy as it eliminates the need for post operative radio therapy or chemo therapy, neither of which should be offered in the first trimester.

Patients with stage I and II lesions presenting in the second trimester can again be offered modified radical mastectomy. Another option is to offer breast conservative surgery followed immediately by chemotherapy and postpartum irradiation.

Patients should be advised to avoid pregnancy for 2 years following treatment of stage I and II CA, and for 5 years for stage III and to avoid pregnancy for stage IV.

Females should also avoid breast feeding during chemotherapy.

Termination of pregnancy has not been shown to increase survival.

Hormone-replacement therapy للأطلاع

Hormone-replacement therapy (HRT) does not appear to increase significantly the risk of developing breast cancer unless taken for prolonged periods (over 10 years), and perhaps in certain high-risk groups. HRT may, however, prolong symptoms of benign breast disorder and make mammographic appearances more difficult to interpret.

Patients who develop breast cancer whilst on HRT appear to have a more favourable prognosis. The consequences in terms of recurrence in women using HRT following breast cancer are unknown.

Familial breast cancer للأطلاع

Recent developments in molecular genetics and the identification of a number of breast cancer predisposition genes (BRCA1, BRCA2) have done much to stimulate interest. Women whose breast cancer is due to an inherited genetic change actually account for less than 5 per cent of all breast cancers

The BRCA1 gene has been cloned and is located on the long arm of chromosome 17 (17q). The gene frequency in the population is approximately 0.0006. **BRCA2** is located on chromosome 13q. Women who are thought to be gene carriers may be offered breast screening (and ovarian screening in the case of **BRCA1**, which is known to impart a 50 per cent lifetime risk of ovarian cancer), usually as part of a research programme, or may be offered genetic counselling and mutation analysis. Those who prove to be 'gene positive' have an 80 per cent risk of developing breast cancer, predominantly whilst premenopausal. Many will opt for prophylactic mastectomy, although this does not completely eliminate the risk.

For those with a positive family history who are unlikely to be carriers of a breast cancer gene, which will comprise the great majority of women, there is no currently proven preventive or screening manoeuvre. Thus these women are best served by being assessed and followed up, if necessary, in a properly organised research family history clinic.

Sentinel lymph node biopsy of the breast. (SLN)

Lymphatic mapping & sentinel lymph node biopsy is relatively new procedure that allow the surgeon to confirm or rule out axillary node involvement without performing a standard axillary dissection. So it is indicated for clinically node negative disease.

The technique based on the theory that the lymphatic channels draining the primary breast tumour initially drain to a single SLN in the regional basin, which can be identified by means of intradermal injection of a vital blue dye, a radio colloid, or both.

A small incision is then made in the regional basin (Which is usually the axilla in breast cancer patients), & the stained SLN is identified (either with a hand held gamma probe or by direct visualization) excised & analyzed histologically.

The technique involve injection of dye in either subareolar or peri tumoural location. The dye used is either radio colloid or 1% isosulfan blue. The optimal interval from injection to identification of the sentinel nodes in surgery is 2 hours for the radioisotope and 5 minutes for the isosulfan blue

Currently standard axillary dissection is recommended for patients who have positive SLN.

Axillary lymph node status is the best prognostic index.

Positive axillary lymph nodes identification has the advantages of:

- 1) Axillary lymphadenopathy is an indicator of metastatic potential.
- 2) For staging CA breast.
- 3) To determine whether the patient need chemotherapy or not (the lymphadenopathy is an indication for chemo therapy).

Carcinoma of the male breast

Carcinoma of the male breast accounts for less than 2 per cent of all cases of breast cancer. The known predisposing causes include gynaecomastia and excess endogenous or exogenous oestrogen. As in the female it tends to present as a lump and is most commonly an infiltrating ductal carcinoma.

Treatment

Stage for stage the treatment is the same as for carcinoma in the female and prognosis depends upon stage at presentation. Adequate local excision, because of the small size of the breast, should always be with a mastectomy

NOTE

Simply being a female is the main risk factor for developing breast Cancer

GOMFORTABLE NOTE للاطلاع

Age	percentage	Age	percentage
By age 25	1 in 19608	By age 60	1 in 24
By age 30	1 in 2525	By age 65	1 in 17
By age 35	1 in 622	By age 70	1 in 14
By age 40	1 in 217	By age 75	1 in 11
By age 45	1 in 93	By age 80	1 in 10
By age 50	1 in 50	By age 85	1 in 9
By age 55	1 in 33	Ever	1 in 8

(1987—1988 Cancer incidence rates, NCI, USA.)

Risk of developing malignancy in association with benign breast pathology للاطلاع

These risks according to the different histological features found at biopsy.

❖ **Benign pathology with no increased risk include:**

- Adenosis, sclerosing or floride- apocrine metaplasia.
- Cyst macro or micro- ductectasia- fibroadenoma
- Fibrosis- hyperplasia- mastitis- periductal mastitis- squamous metaplasia.

❖ **Pathologies associated with slightly increase risk (1.5-2 times) are:**

- Hyperplasia, moderate or florid, solid or papillary.
- Papilloma with fibro vascular core.

❖ **Pathologies associated with moderately increased risk (5 times) include.**

- Atypical hyperplasia (ductal or lobular)

❖ **Pathologies that are associated with insufficient data to assign at risk include.**

- Solitary papilloma of lactiferous sinus.
- Radial scar lesion

The male breast**gynaecomastia,****Grading**

Grade I mild breast enlargement with out skin redundancy

Grade II a moderate breast enlargement without skin redundancy.

Grade II b moderate breast enlargement with skin redundancy.

Grade III marked breast enlargement with skin redundancy and ptosis which simulate a female breast.

Causes of gynaecomastia

- 1) **Physiological gynaecomastia** which usually occur during 3 phases of life.
- 2) **Neonatal period**
- 3) **Adolescent**
- 4) **Senescence.**

In all of these periods, there is excess of estrogen in relation to the circulating testosterone.

- Neonatal gynaecomastia caused by placental oestrogen on neonatal breast tissue.
 - In adolescence, there is an excess of oestradiol relative to testosterone.
 - In senescence, the circulating level of testosterone decrease.
- 5) oestrogen excess result from increase secretion of oestradiol from the testicles or from non testicular tumour e.g. CA lung, protein & fat deprivation, endocrine disorders (e.g. hyper or hypothyroidism) and hepatic disease (as alcoholic or non alcoholic cirrhosis)
 - 6) androgen deficiency which occur due to;

*Increase circulating testosterone binding globulin.

*Senescence gynaecomastia occur between the ages of 50-70 years *Klinefelter syndrome * primary testicular failure which may be caused by ACTH deficiency or hereditary defect of androgen synthesis & congenital anorchia.

*Secondary testicular failure may result from trauma, orchitis cryptorchidism. * & renal failure.

7) Drug induced as digitals, estrogen, anabolic steroids cimetidin, ketocanazole, phenytoin, and spironolactone, diazepam, anti neoplastic agents, rserpin, verapamil & furosemide.

Treatment of gynaecomastia

It depends on the cause

- * When gynaecomastia caused by androgen deficiency then testosterone administration may cause regression of gynaecomastia.
- * When caused by medication, discontinue its use if possible.
- * When caused by endocrine defect, receive specific treatment.
- * If progressive gynaecomastia and does not respond to other therapies, then do surgical treatment (mastectomy) preserving the nipple and areola.

Carcinoma of the male breast

Carcinoma of the male breast accounts for less than 2 per cent of all cases of breast cancer. The known predisposing causes include gynaecomastia and excess endogenous or exogenous oestrogen. As in the female it tends to present as a lump and is most commonly an infiltrating ductal carcinoma.

Treatment

Stage for stage the treatment is the same as for carcinoma in the female and prognosis depends upon stage at presentation. Adequate local excision, because of the small size of the breast, should always be with a mastectomy

Other tumours of the breast للأطلاع**Lipoma**

A true lipoma is very rare.

Sarcoma of the breast

Sarcoma of the breast is usually of the spindle-cell variety, and accounts for 0.5 per cent of malignant tumours of the breast. Some of these growths arise in an intracanalicular fibroadenoma or may follow previous radiotherapy, e.g. for Hodgkin's lymphoma many years previously. It may be impossible to distinguish clinically a sarcoma of the breast from a medullary carcinoma, but areas of cystic degeneration suggest a sarcoma and on incising the neoplasm it is pale and friable. Sarcoma tends to occur in younger women between the ages of 30 and 40. Treatment is by simple mastectomy followed by radiotherapy. The prognosis depends on the stage and histological type.

Metastases

On rare occasions, cancer elsewhere may present with a metastasis in the breast. The breast is also occasionally infiltrated by Hodgkin's disease and other lymphomas.

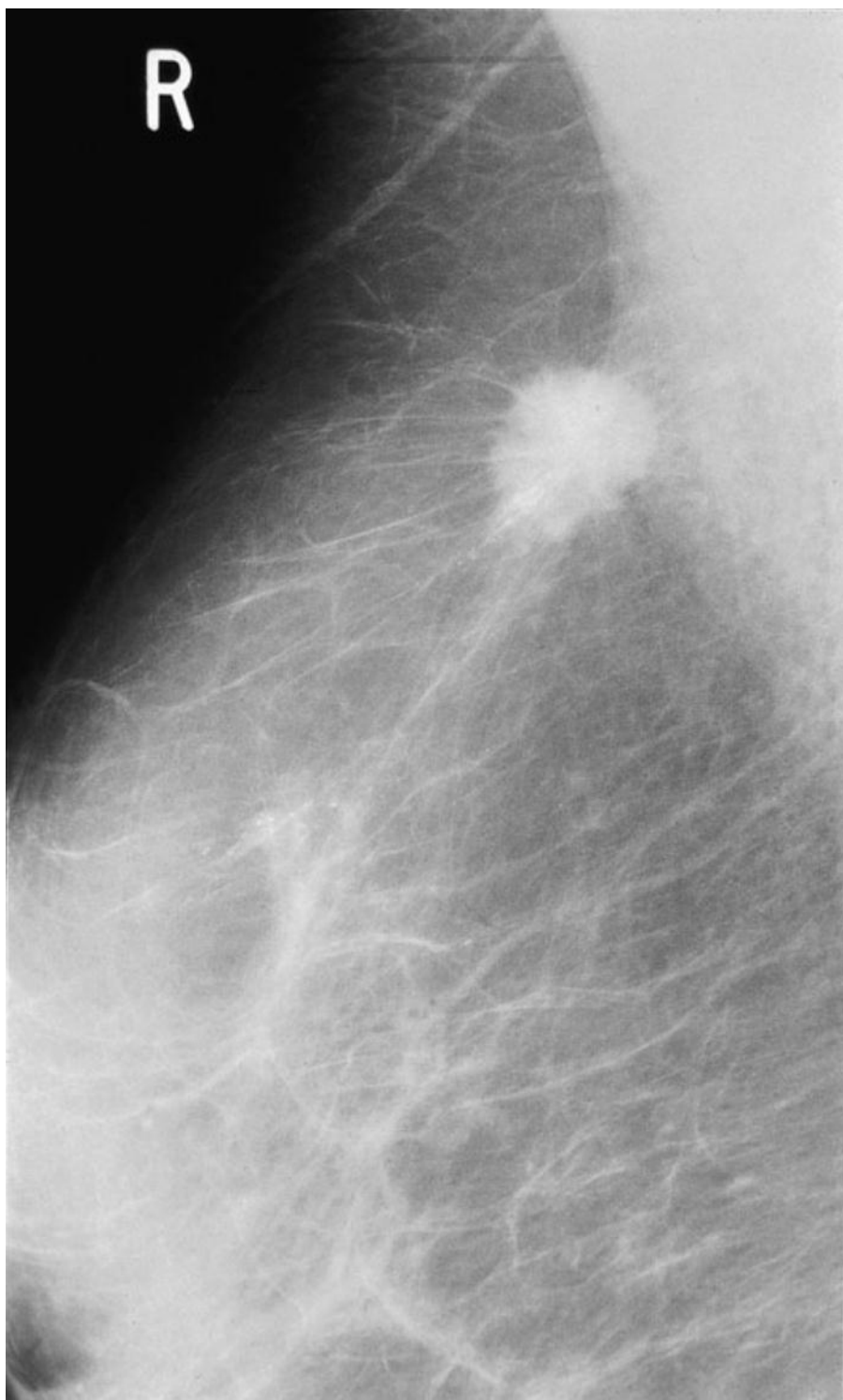

Figure 50.2 Mammogram showing a carcinoma

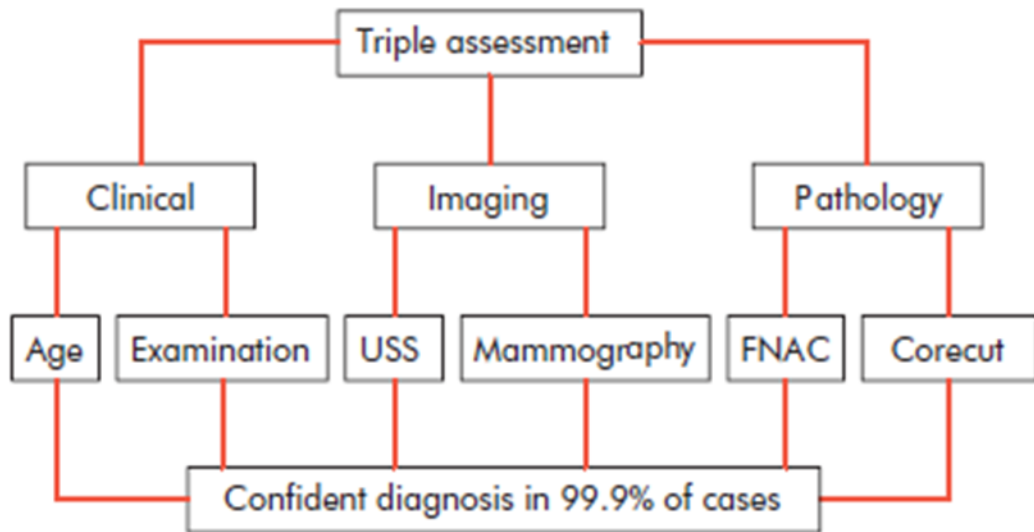
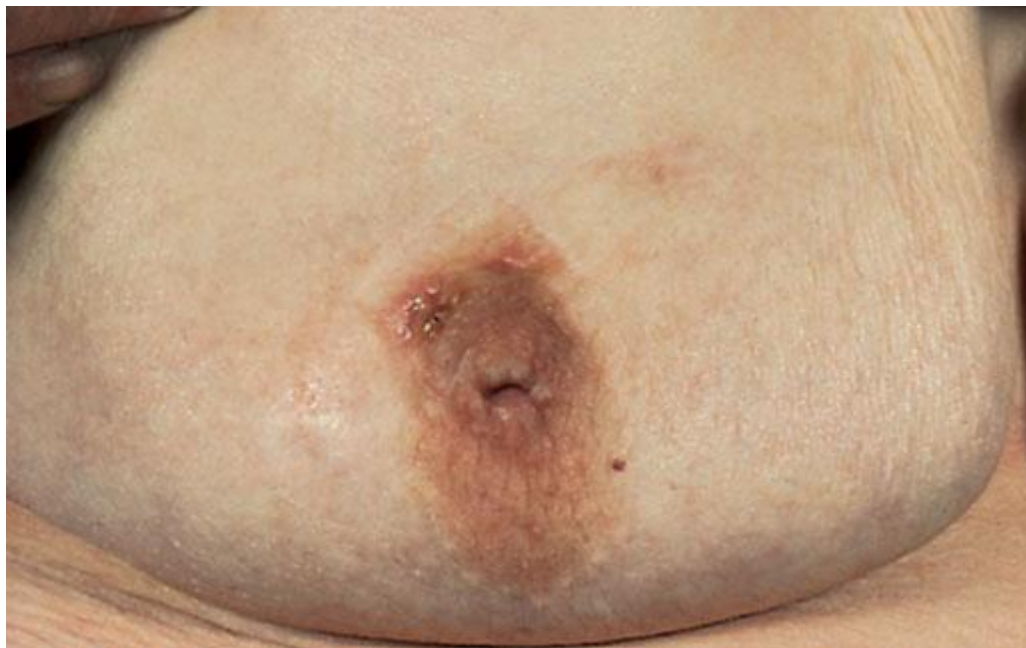

Figure 50.8 Triple assessment of breast symptoms. USS, ultrasound scan.



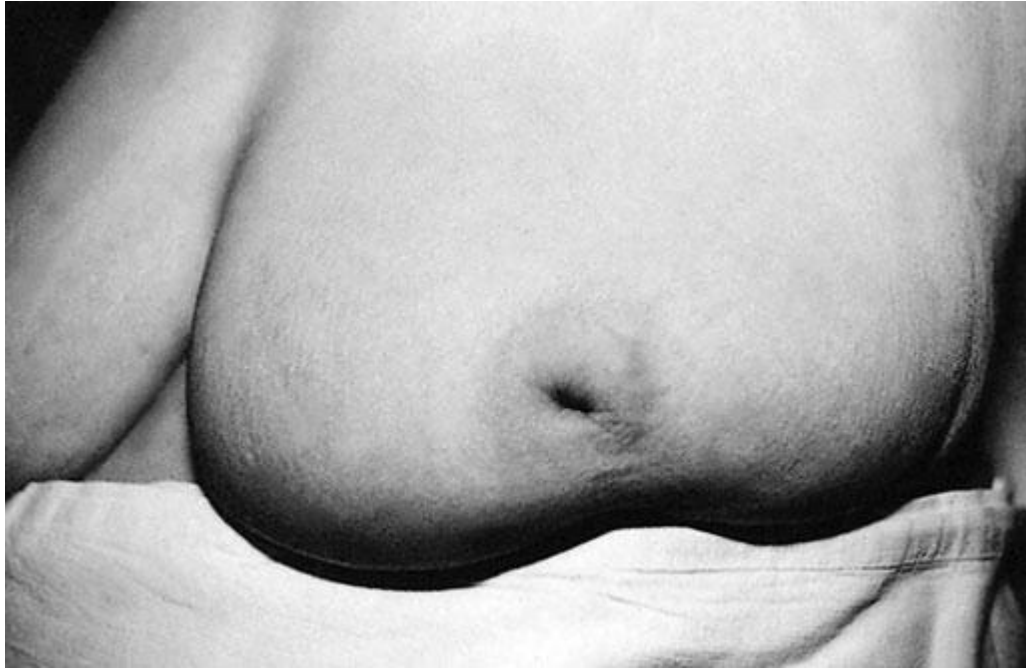

Figure 50.10 Recent nipple retraction. (a) Slit-like retraction of duct ectasia with mammary duct fistula. (b) Circumferential retraction with underlying carcinoma.

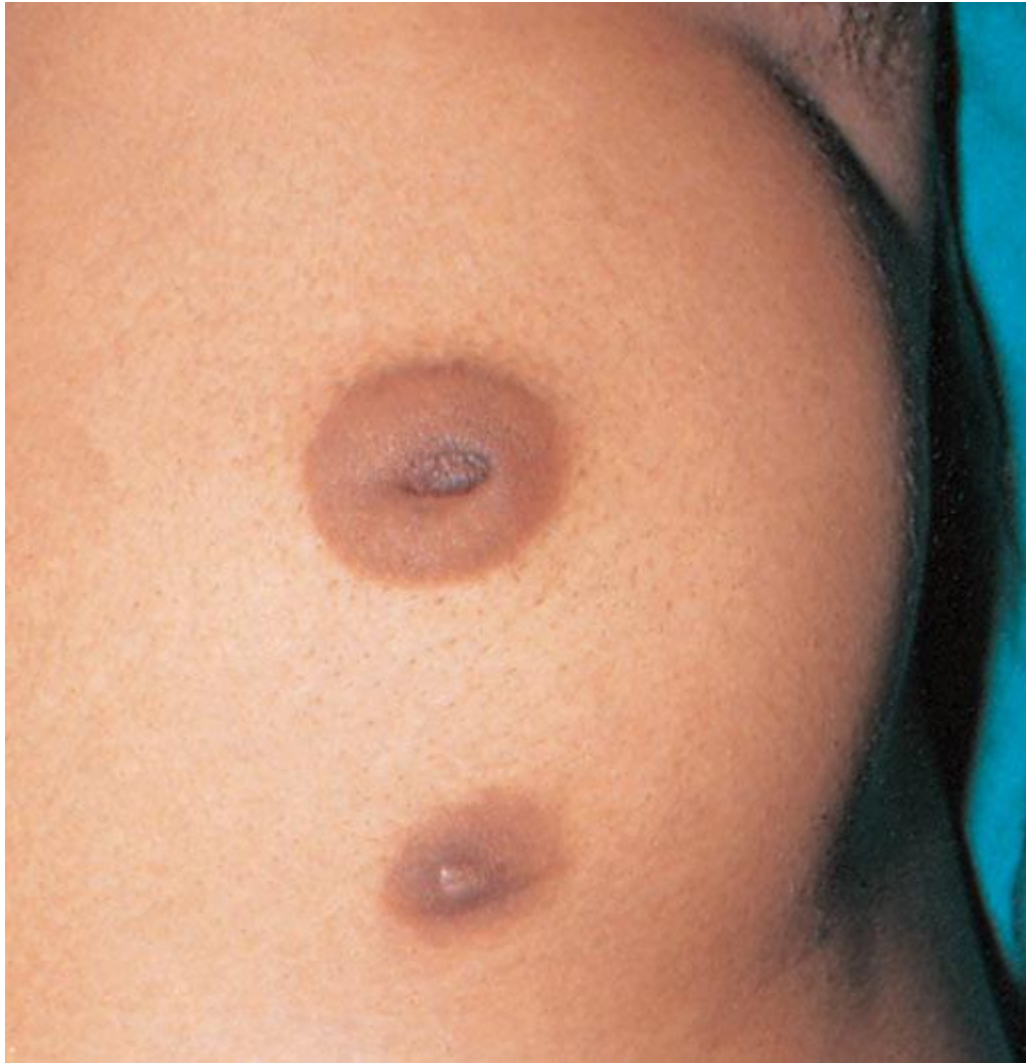

Figure 50.9 Accessory nipple with congenital retraction of the normal nipple.

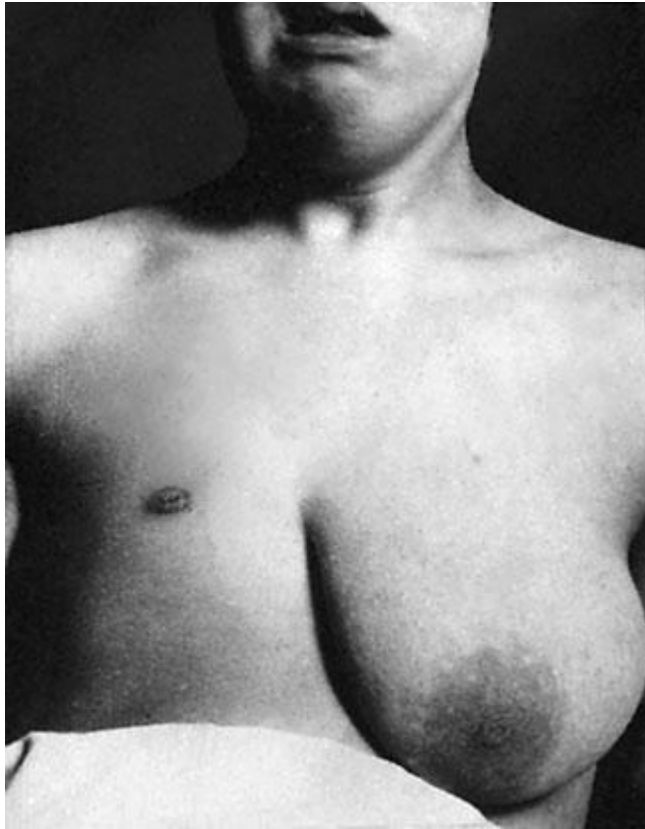


Figure 50.11 Congenital absence of the right breast.

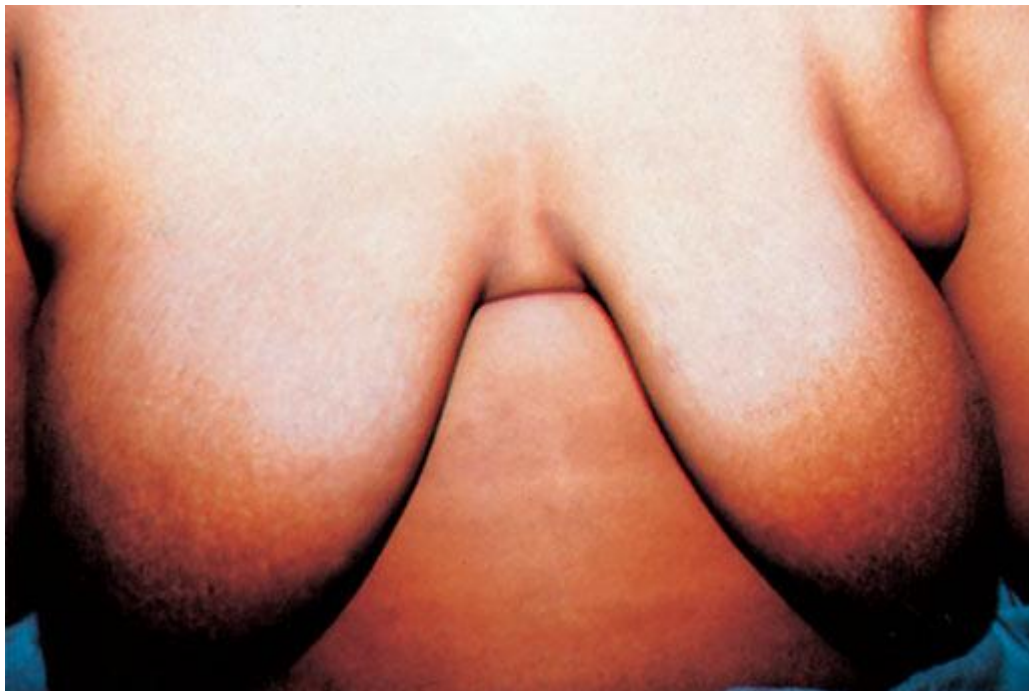

Figure 50.12 Bilateral accessory breasts.

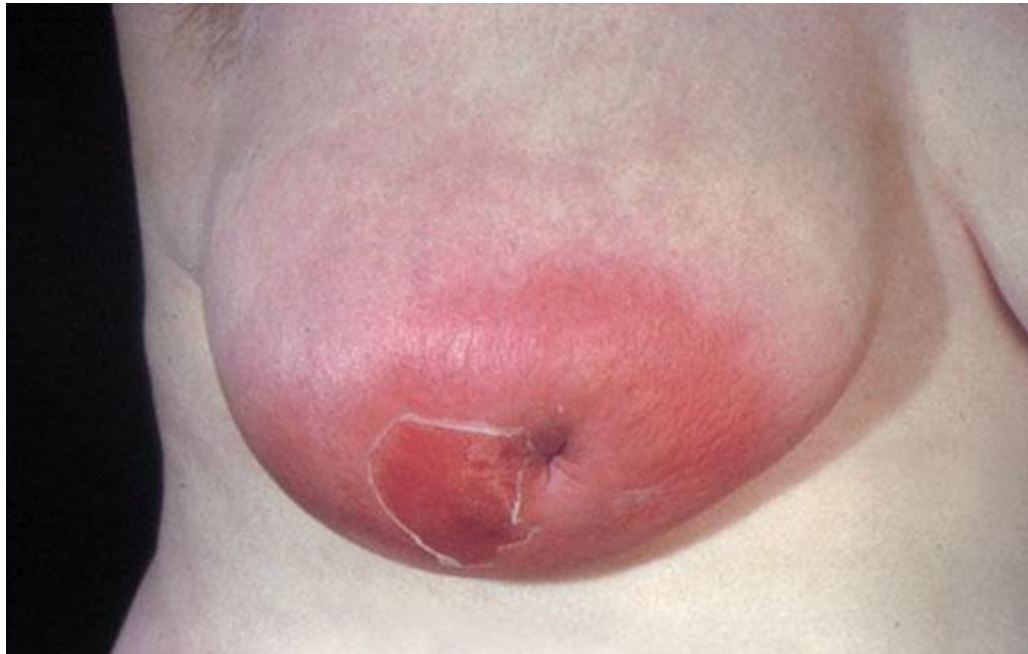

Figure 50.14 Large breast abscess.

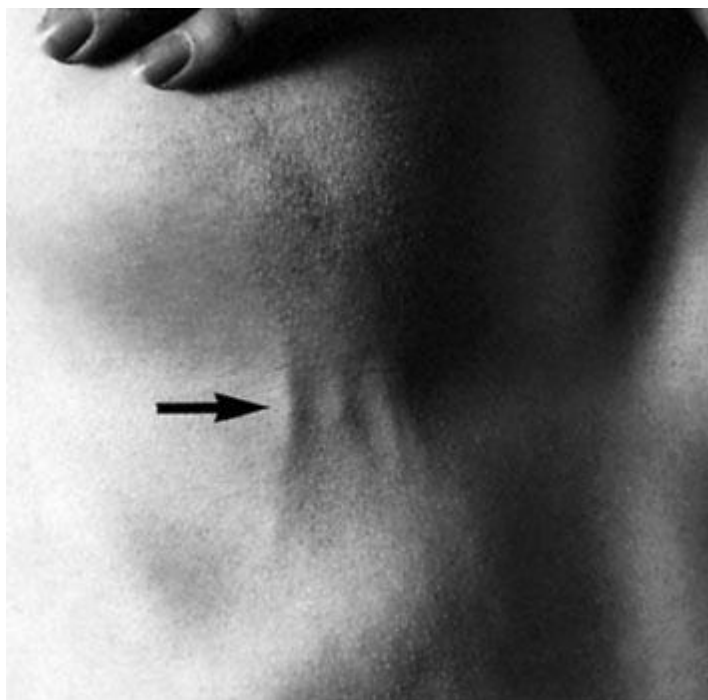


Figure 50.16 Mondor's disease under the right breast (arrow).

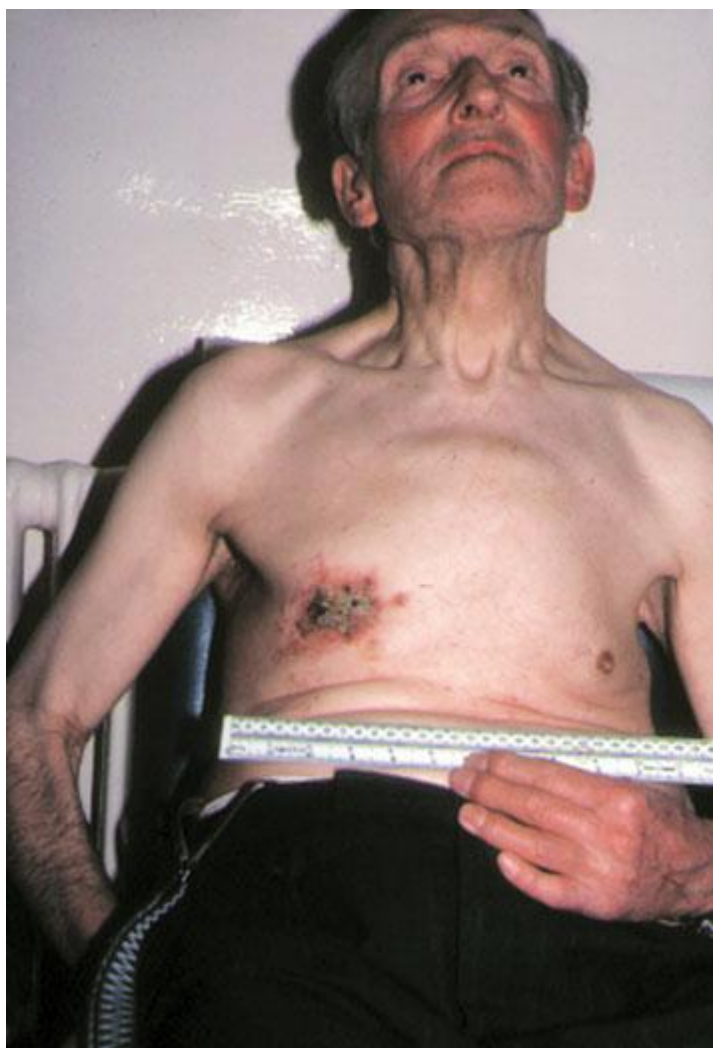

Figure 50.33 Carcinoma of the male breast